

A MIRACLE TRIAL ON VARIED PRESENTATIONS OF MUCORMYCOSIS – INTRALESIONAL AMPHOTERICIN

A. Nandhini¹, Ganapathi Rajesh², Hemapriya³

¹Associate Professor, Department of Ophthalmology, Madras Medical College, India.

²Professor, Department of Ophthalmology, Theni Medical College, India.

³Assistant Professor, Department of Ophthalmology, Madras Medical College, India.

Received : 09/01/2023
Received in revised form : 15/02/2023
Accepted : 27/02/2023

Keywords:

Intralesional Amphotericin,
Mucormycosis, Dacryocystitis, Covid.

Corresponding Author:

Dr. Nandhini Arumugam,

Email: dr.nandhiniarumugam@gmail.com

DOI: 10.47009/jamp.2023.5.4.151

Source of Support: Nil,

Conflict of Interest: None declared

Int J Acad Med Pharm
2023; 5 (4); 761-764



Abstract

Background: Mucormycosis is an opportunistic fungal disease that commonly presents as cutaneous or rhinocerebral infections associated with immunocompromised states. It may rarely present with involvement of lacrimal sac. The aim of this study is to understand the efficacy of amphotericin B given intralesionally into lacrimal sac in dacryocystitis and lacrimal sac abscess in patients with Rhino- orbital mucormycosis. In this case series, 15 radiologically and histopathologically confirmed cases of Rhino orbital mucormycosis presented with dacryocystitis or lacrimal sac abscess. Lacrimal syringing and clinical correlation was done for all these patients. Medical therapy in the form of intravenous amphotericin B (5mg/kg/day) was initiated for all patients in correct dosage with duration according to the protocol. All the patients were treated with multiple doses of intralesional amphotericin B after reconstitution (3.5mg/ml). A single dose contained 0.5ml reconstituted amphotericin B given into the sac or over the lesion after informed consent. The size and induration of the lesion was measured before starting on the next day after treatment and 2 weeks after initiation of treatment. Of the patients followed up 10 patients showed complete regression of the patients while 5 patients showed reduction in size of the lesion with 2 weeks of follow up post treatment were observed. 9 out of 15 patients gave a history of being tested positive for COVID 19. 12 out of the 15 patients had type 2 diabetes mellitus as a comorbidity. Mucormycosis is an opportunistic fungal infection of the zygomycete family that can cause various types of infections. Mucormycosis is characterized by tissue necrosis due to an invasion of blood vessels and subsequent thrombosis, which usually follows a rapid progression. Hence it is crucial for an appropriate and effective treatment to be given promptly to prevent arrest of progression.

INTRODUCTION

Mucormycosis is a rare, rapidly progressive and a fulminant, life-threatening, opportunistic infection. Although it most commonly manifests in diabetic patients, its presence in other immunologically compromised patients cannot be ruled out. Caused by fungi of the order of Mucorales. It was first described by Paltauf in 1885. It is the third most common opportunistic fungal infection after candidiasis and aspergillosis. Rhizopus, along with Mucor and Lichtheimia account for about 70–80% of all the cases of mucormycosis. These saprophytic organisms exist in the soil, manure, fruits, starchy foods and are frequently found to colonize the oral mucosa, the nasal mucosa, the paranasal sinus, orbit and the pharyngeal mucosa of asymptomatic patients. Moreover, the sudden surge and

exponential rise in the number of post COVID – 19 mucormycosis led to various uncommon presentations such as dacryocystitis and lacrimal sac abscess. Amphotericin B, a macrolide polyene antifungal, is obtained from soil actinomycete *Streptomyces nodosus* via the process of fermentation. Because amphotericin B is amphoteric and water-insoluble, only parenteral formulations are available. In previous studies it has been successfully used intralesionally in the treatment of leishmaniasis and sporotrichosis.^[2,3,4]

Aim and Objective

Aims to understand the efficacy of amphotericin given intralesionally into lacrimal sac in dacryocystitis and lacrimal sac abscess in patients with rhino-orbital mucormycosis.

MATERIALS AND METHODS

Consecutive patients diagnosed radiologically and histopathologically with invasive mucormycosis and presenting with dacryocystitis and lacrimal sac abscess were admitted and included in the study.

History regarding previous history of Diabetes, COVID 19, treatment with steroids, etc. were elicited. Thorough clinical examination including uncorrected visual acuity, extraocular movement evaluation & pupillary assessment were done to quantify and stage the disease clinically.

Indirect ophthalmoscopy was performed to rule out central retinal artery occlusion, disc edema, etc. CT PNS was performed in all patients under evaluation. MRI Brain with orbit was done in patients in whom intracranial spread in the form of cavernous sinus thrombosis, temporal lobe abscess of the disease and when optic nerve involvement is suspected.

Medical therapy in the form of intravenous amphotericin B (5mg/kg/day) was initiated for all patients in correct dosage with duration according to the protocol.

Lacrimal sac syringing was done for all the patients included in the study and the findings were clinically correlated. All the patients were treated with multiple doses of intralesional amphotericin B after reconstitution (3.5mg/ml). A single dose contained 0.5ml reconstituted amphotericin B given into the sac or over the lesion after informed consent. The size and induration of the lesion was measured before starting, on the next day after treatment and 2 weeks after initiation of treatment.

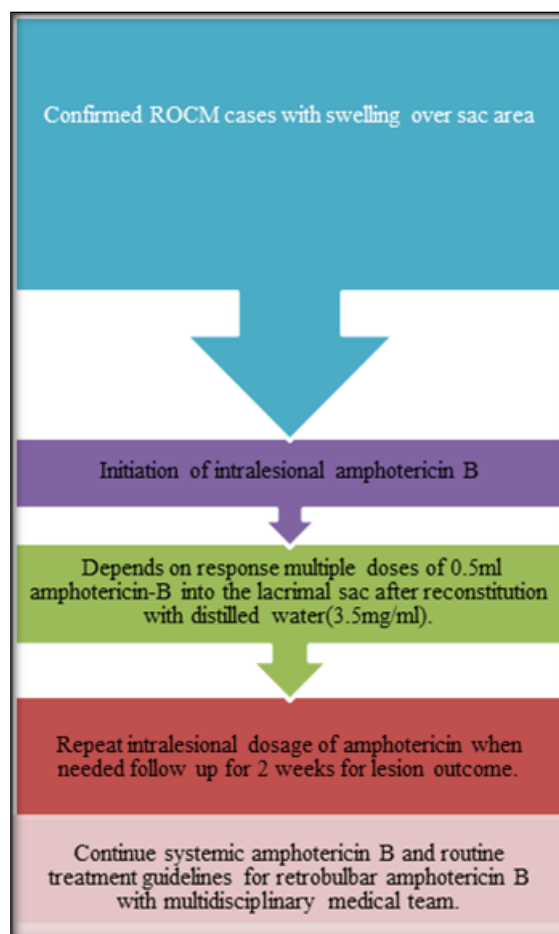


Figure 1: Treatment Protocol

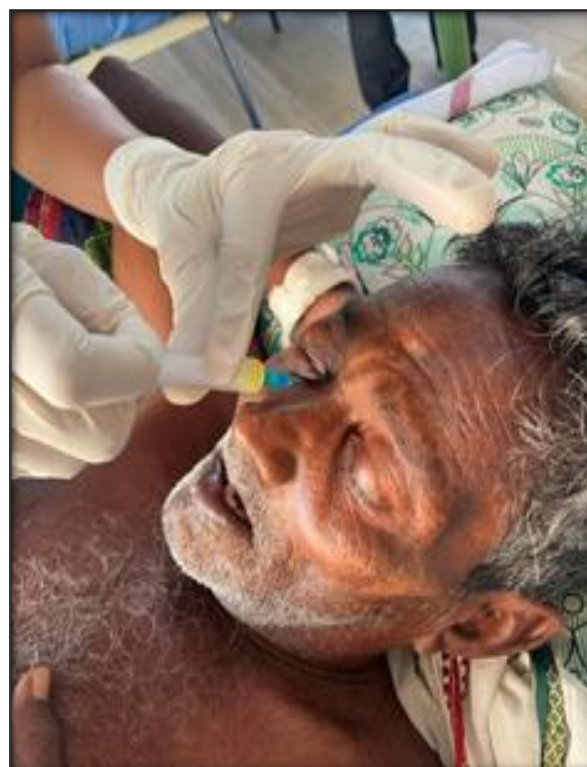

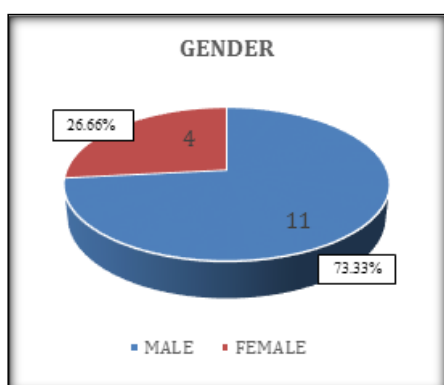
Figure 2: Demonstration of intralesional injection

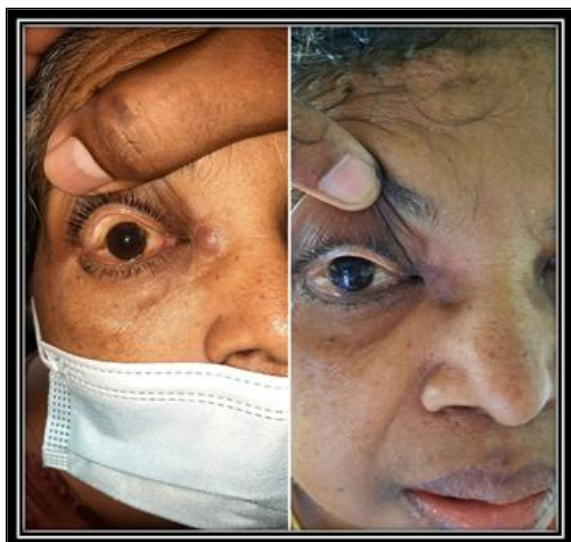

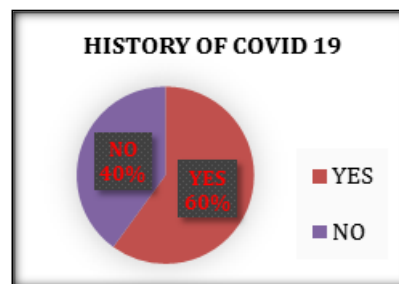
Figure 3: Before Initiation of Treatment after Completion of Three Doses

RESULTS

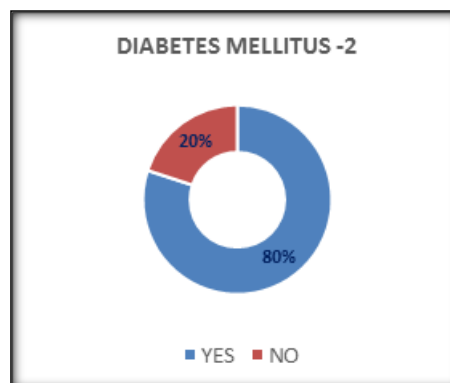
A total of 15 patients diagnosed as rhino-orbital mucormycosis and presenting with dacryocystitis and lacrimal sac abscess were included in this study. Of these 15, 11 patients were males (73.3%) and 4 were females (26.6%). 9 out of 15 patients gave a history of being tested positive for COVID 19(60%). 12 out of the 15 patients had type 2 diabetes mellitus (80%) as a comorbidity. 11 patients in this study gave a history of treatment with steroids (73.3%) prior to presentation. Of the patients followed up 10 patients showed complete regression (66.66%) of the patients while 5 patients showed reduction in size (33.33%) of the lesion with 2 weeks of follow up post treatment were observed. Based on anatomical staging of ROCM, 7 out of 15 patients were found to be in stage 3b (46.6%) followed by 4 out of the 15 patients belonging to stage 3c (26.6%). 13 out of the 15 patients showed resolution or reduction in size with 3 doses of intralesional amphotericin B (86.66%), 2 out of 15 patients required more than 3 doses (13.33%) of the treatment. [FIGURE 4]



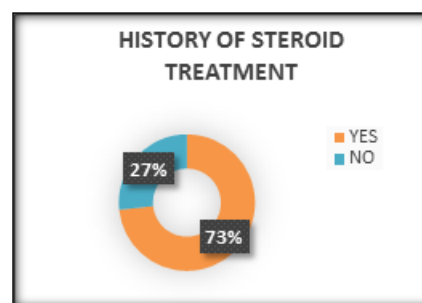
A



B



C



D

Figure 4: A) Gender Distribution. B) Diabetic status. C) Covid 19 status. D) History of previous steroid treatment

DISCUSSION

Amphotericin B is an antifungal and antiparasitic drug with broad spectrum of activities against the organisms with ergosterol in their membranes. It is commonly used as a systemic agent with intravenous administration. However, because of its toxic effects on the body organs particularly kidney, it is generally used only after other treatments have failed. Topical or local administration of reconstituted amphotericin B have been successful in largely circumventing these systemic side effects. Several studies have shown that transcutaneous retrobulbar amphotericin B has provided good efficacy in the treatment of rhino-orbital mucormycosis. The sudden surge and exponential rise in the number of Post COVID – 19 mucormycosis led to various uncommon presentations such as dacryocystitis and lacrimal sac abscess. These uncommon presentations were not

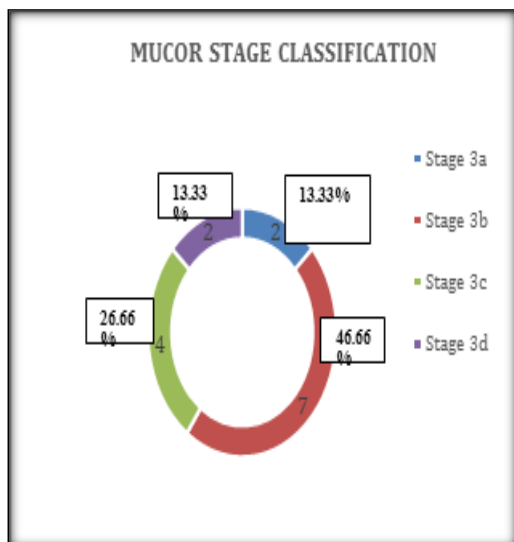
responding positively to the conventional methods of treatment.

The authors of this study reviewed plenty of literature and were unsuccessful in finding much data on the challenging situation that was facing them currently. The authors came across a study by Goyonlo et al on the efficacy of transcutaneous amphotericin on treatment of cutaneous leishmaniasis.⁵ The authors decided to implement a novel treatment trial of amphotericin B given intralesionally into lacrimal sac in dacryocystitis and lacrimal sac abscess in patients with Rhino- orbital mucormycosis at a single tertiary care centre.⁶

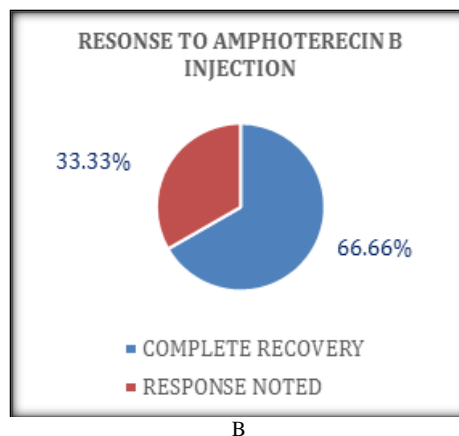
The present study described therapeutic results for intralesional injection of amphotericin B in 15 patients diagnosed with rhino-orbital mucormycosis and presenting with dacryocystitis and lacrimal sac abscess. Of the patients followed up 10 patients showed complete regression (66.66%) of the patients while 5 patients showed reduction in size (33.33%) of the lesion with 2 weeks of follow up post treatment were observed.

A working staging of ROCM proposed by Honavar et al was used in this study to categorize the stage of ROCM.⁷ Based on this staging of ROCM, 7 out of 15 patients were found to be in stage 3b (46.6%) followed by 4 out of the 15 patients belonging to stage 3c (26.6%).

86.66% of the patients showed resolution or reduction in size with 3 doses of intralesional amphotericin B.



A



B

Figure 5: Staging and Treatment response

CONCLUSION

Mucormycosis involves orbit and other ocular structures. Ophthalmologists may be the first to see the patient with this highly morbid condition. It is important this should be considered as one of the differential diagnosis lists as delay in establishing diagnosis and initiating therapy could prove fatal. Varied and uncommon presentations of mucormycosis when encountered could prove to be challenging and may present a treatment dilemma. Based on the results of this study, the authors concluded that intralesional amphotericin B could be a promising alternative therapy for patients presenting with varied/ uncommon presentations of ROCM. Uncontrolled diabetes was found to be the strongest risk factor associated with varied presentations of mucormycosis followed by COVID-19 history.

Financial support and sponsorship.

Nil.

Conflicts of interest there are no conflicts of interest

REFERENCES

1. David EA, Thomas M, John IM. Treatment of rhinocerebral mucormycosis with intravenous, interstitial, and cerebrospinal fluid administration of amphotericin B: case report. *Neurosurgery*. 1998 Mar 1;42(3):644-9.
2. Gremião ID, Schubach TM, Pereira SA, Rodrigues AM, Honse CD, Barros MB. Treatment of refractory feline sporotrichosis with a combination of intralesional amphotericin B and oral itraconazole. *Australian Veterinary Journal*. 2011 Sep;89(9):346-51.
3. Yaghoobi R, Maraghi S, Bagherani N, Rafiei A. Cutaneous leishmaniasis of the lid: a report of nine cases. *Korean Journal of Ophthalmology*. 2010 Feb 1;24(1):40-3.